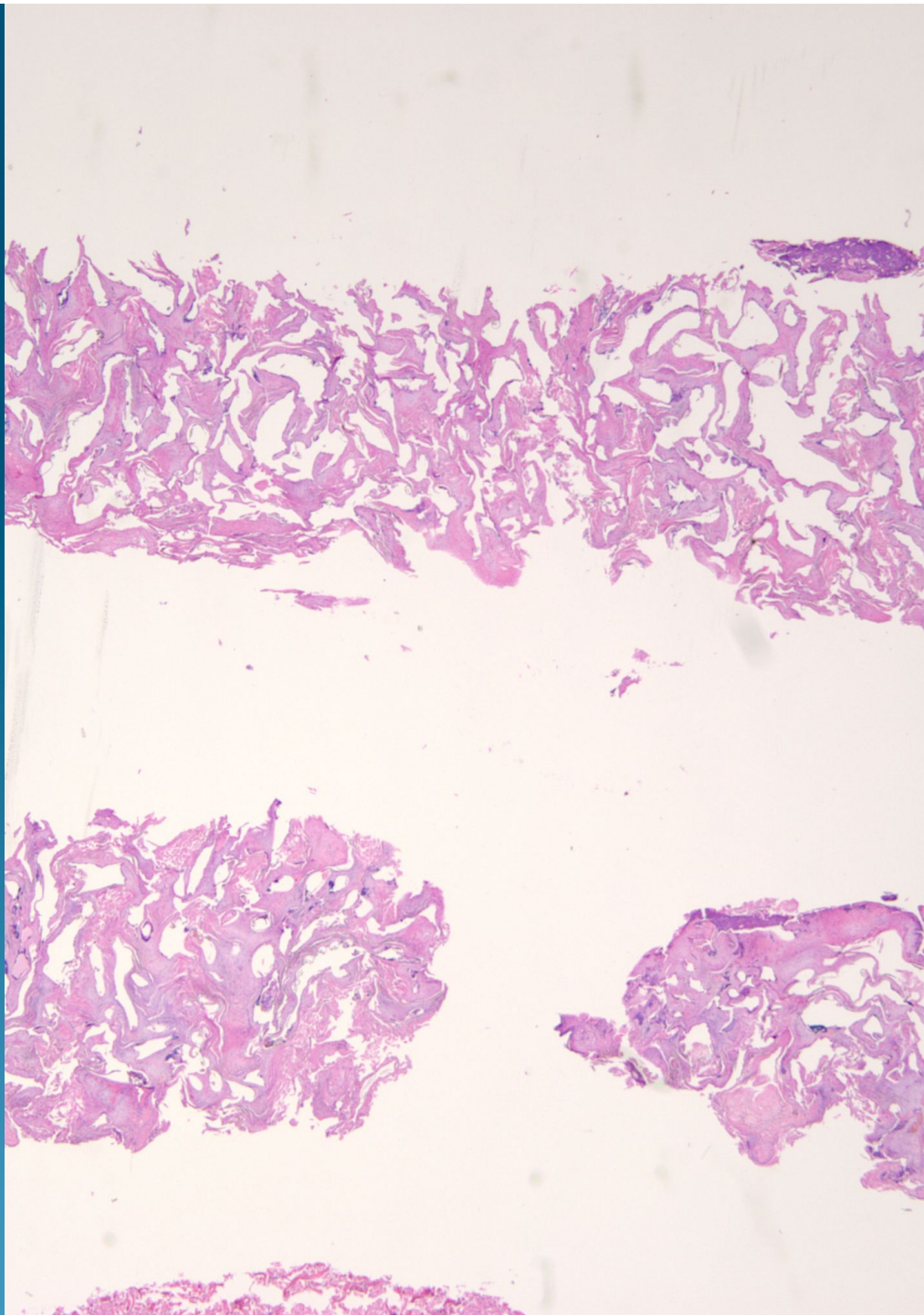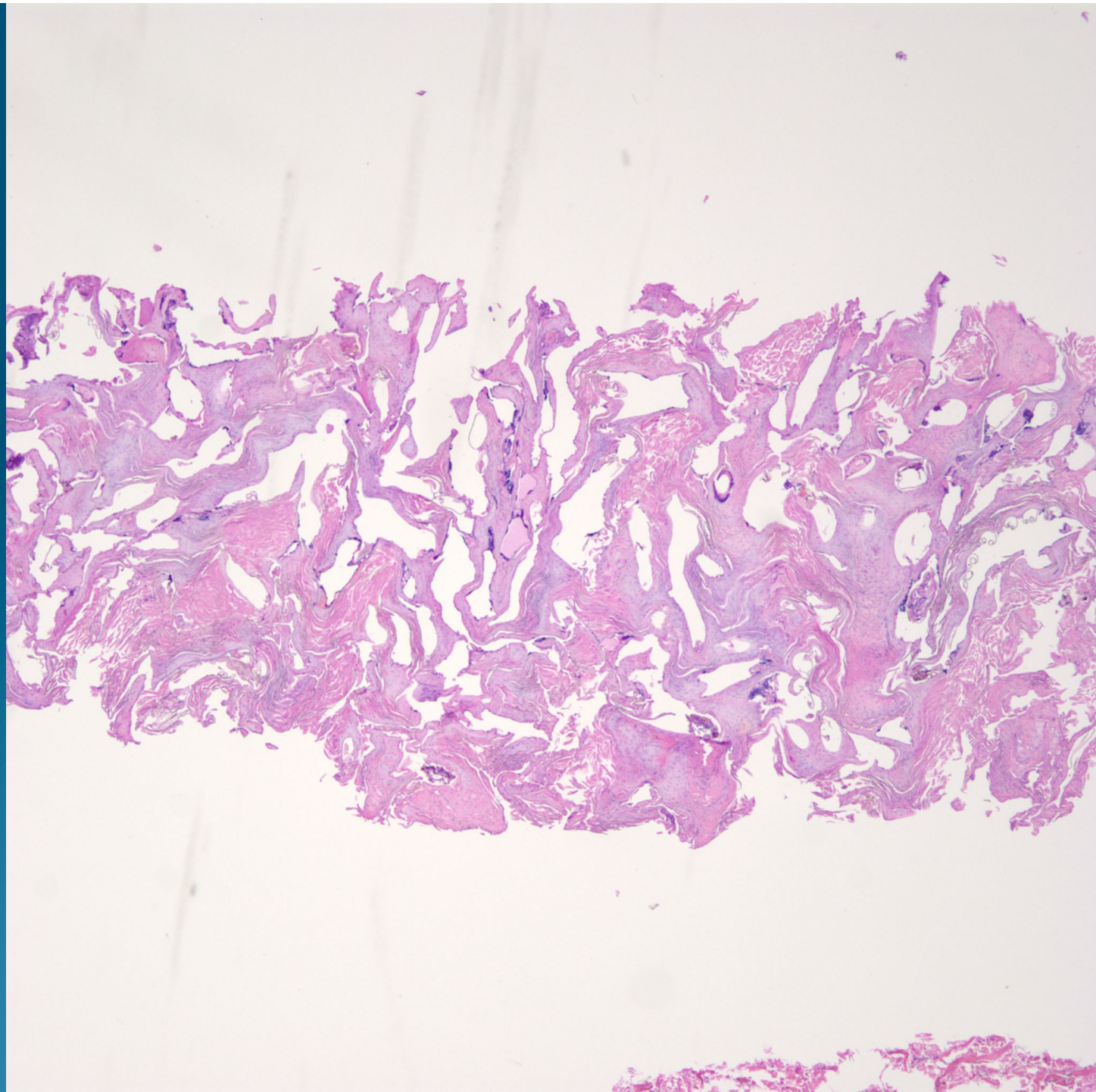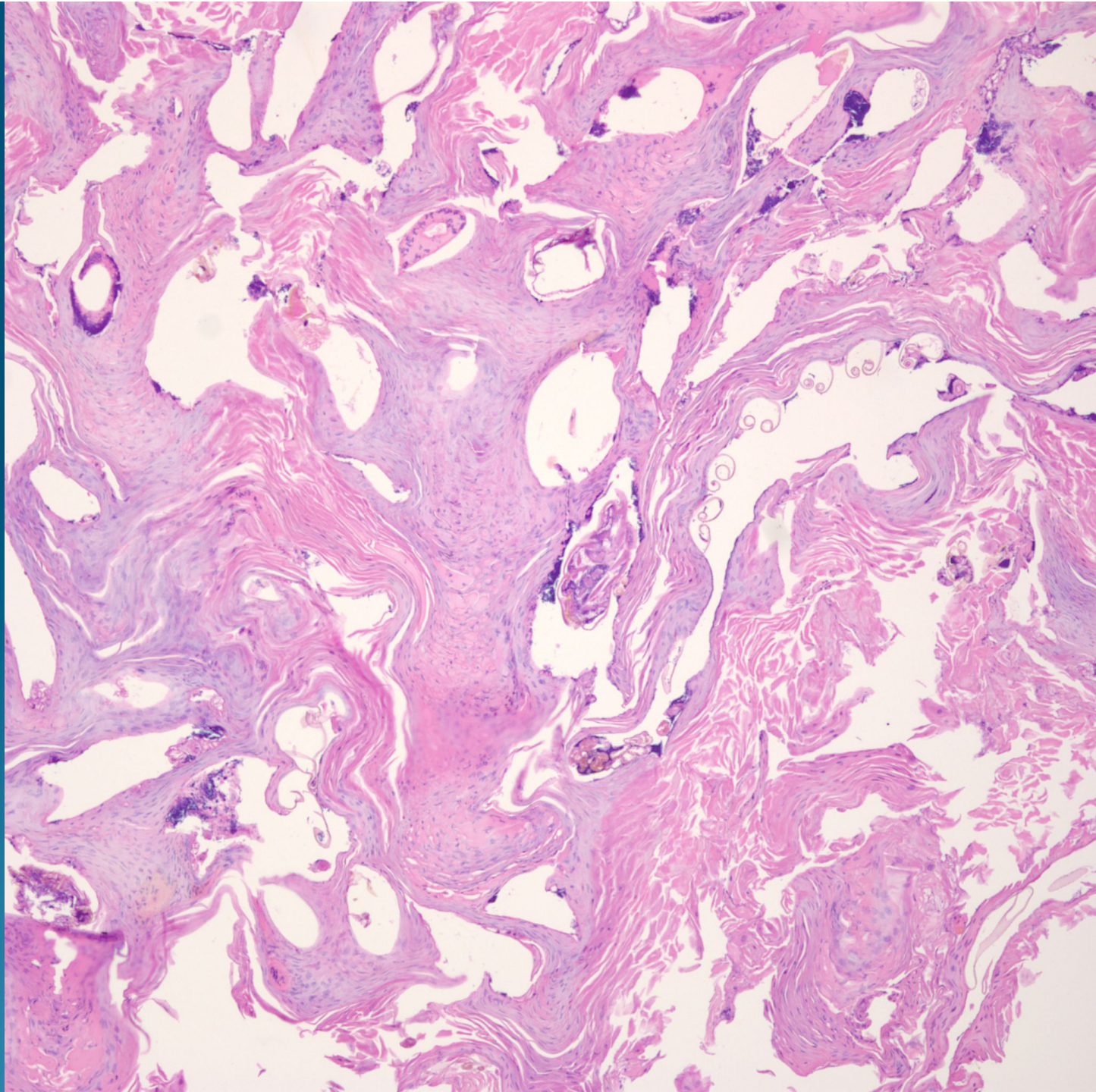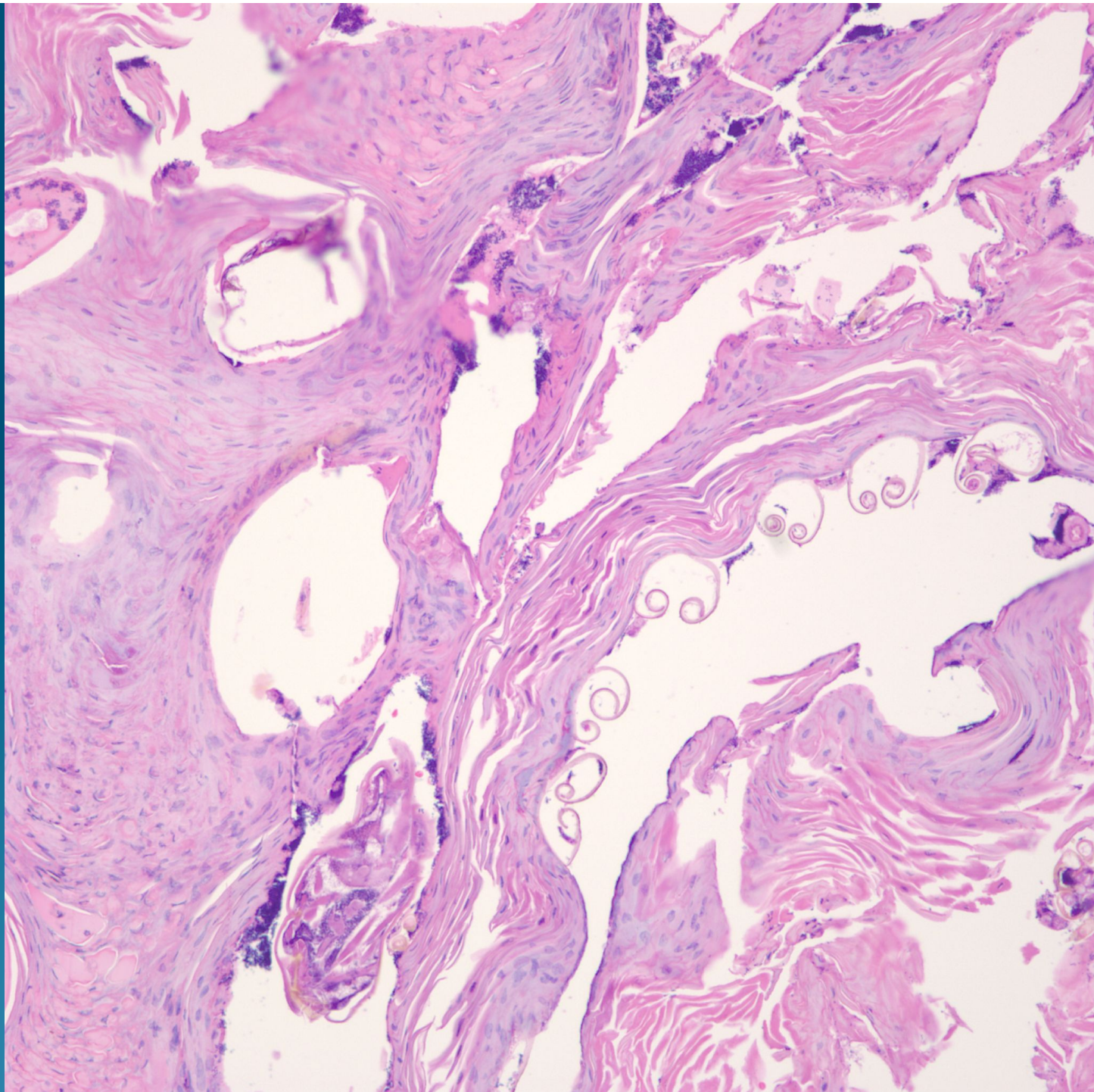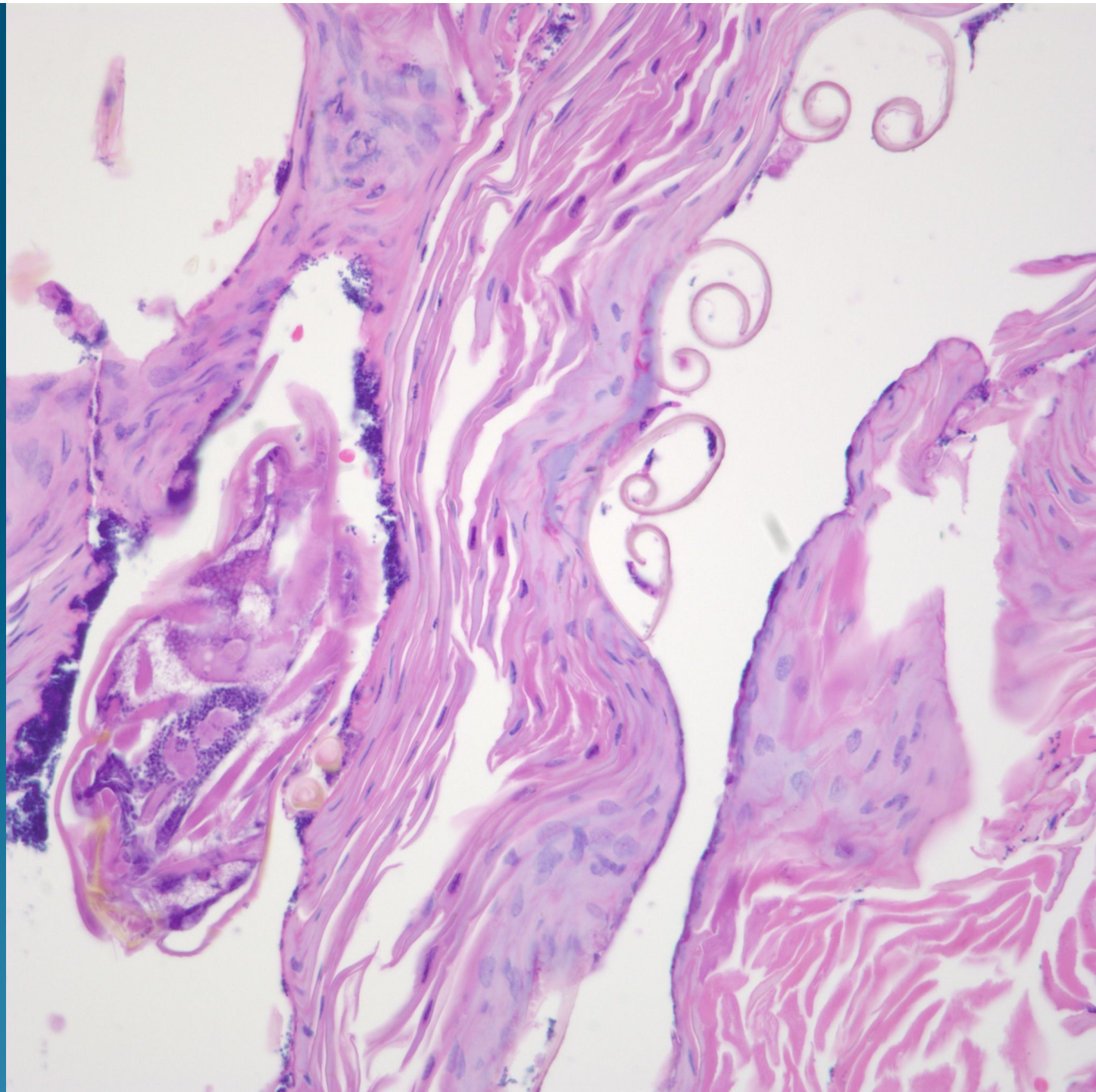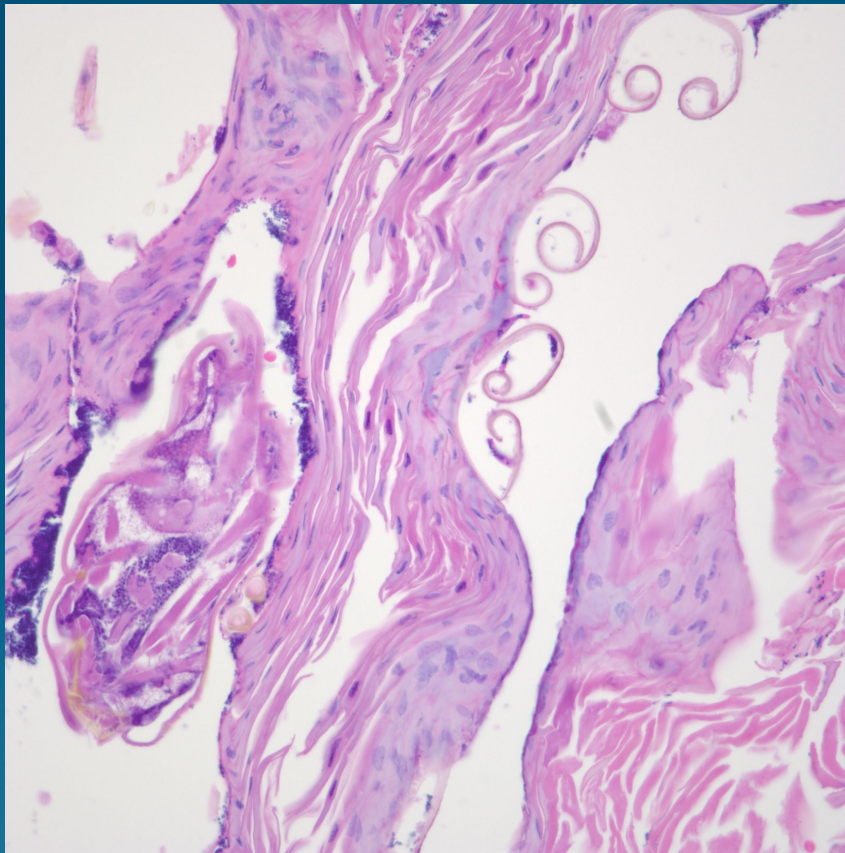


“Football and Moustaches”

What is the diagnosis?

Norwegian Scabies

Pearls



- Extensive infiltration of mites in stratum corneum
- May see scybula (footballs) and moustaches (cuticle of mite)